

# Challenges of Thoracic Endovascular Aortic Repair for Type B Aortic Dissection

Journal of Endovascular Therapy  
 2018, Vol. 25(5) 578–580  
 © The Author(s) 2018  
 Article reuse guidelines:  
[sagepub.com/journals-permissions](http://sagepub.com/journals-permissions)  
 DOI: 10.1177/1526602818795153  
[www.jevt.org](http://www.jevt.org)  


Theodorus M. J. van Bakel, MD<sup>1,2,3</sup>, C. Alberto Figueroa, PhD<sup>1,4</sup>,  
 Joost A. van Herwaarden, MD, PhD<sup>2</sup>, and Santi Trimarchi, MD, PhD<sup>3,5</sup>

## Keywords

aortic dissection, aortic remodeling, intimal flap, postdissection aneurysmal dilatation, stent-graft–induced new entries, stent-graft oversizing, thoracic endovascular aortic repair, type B dissection, wall stress

Feasibility of thoracic endovascular aortic repair (TEVAR) for type B aortic dissection (TBAD) continues to be a subject of debate. Current guidelines recommend optimal medical therapy for acute TBAD with continued imaging surveillance.<sup>1</sup> TEVAR is reserved for patients who present with complications.<sup>1</sup> However, 50% of patients who are initially treated with optimal medical therapy alone develop aneurysmal degeneration of the weakened aortic wall during follow-up.<sup>2</sup>

The study of Menichini et al<sup>3</sup> in the October 2018 issue of the *J EVT* presents 2 patients with aneurysmal dilatation of the thoracic false lumen following TBAD. Both patients were treated with TEVAR, patient 1 in the chronic phase and patient 2 in the subacute phase. Early follow-up results were satisfactory, but at 14-month follow-up a stent-graft–induced new entry tear (SINE) with aneurysmal dilatation was observed at the distal end of the stent-graft in patient 1. The dissected aorta in patient 2 remained stable. With the caveat of the simplistic modeling approach of this analysis, which considered the aorta as a linear elastic material and disregarded the prestress, computational analysis showed higher stress, torsional strain, and wall displacement in patient 1 compared with patient 2. The region of high stress and displacement corresponded well with the location of SINE. The authors conclude that tortuosity, curvature, and thoracic aortic length have a strong influence on local stress distributions and risk of SINE. We agree that patient-specific anatomical features can impose challenges for successful endovascular repair of TBAD and would like to comment on planning TEVAR in such cases.

In TBAD, timing has important implications for the biomechanical properties of the intimal flap.<sup>4</sup> In the acute phase (within 2 weeks from onset of dissection), the intimal flap is still thin and highly mobile. Covering the proximal entry tear with a stent-graft in this phase induces positive aortic remodeling by reducing perfusion of the false lumen, approximating the intima to its original position, and opening the true lumen. This way, TEVAR in the acute phase has

been shown to improve survival compared to optimal medical therapy alone.<sup>5,6</sup> Following the acute phase, the intimal flap becomes thicker and less mobile (Figure 1).<sup>4</sup> After 8 to 12 weeks, TBAD is classified as chronic. TEVAR in the chronic phase is more challenging as the thickened intimal flap does not approximate to the aortic wall as it would in the acute phase.<sup>7</sup> Furthermore, complete thrombosis of the false lumen is less likely to occur due to formation of persistent distal intimal tears that accommodate perfusion of the false lumen after TEVAR.<sup>7</sup> Consequently, aortic remodeling is limited.<sup>8</sup>

Another challenging factor when performing TEVAR for TBAD is the tortuosity of the dissected aorta. Tortuosity increases wall stresses due to the spring-back forces in the stent-graft,<sup>3</sup> reduces stability in the landing zones,<sup>9</sup> and increases hemodynamic displacement forces that can cause stent-graft migration.<sup>10,11</sup> To secure stability, the stent-graft needs to be sized correctly. The proximal and distal landing zone lengths should be at least 2 cm to accommodate safe deployment. If the landing zones are angulated, longer lengths should be considered to provide a larger area of

<sup>1</sup>Department of Surgery, University of Michigan, Ann Arbor, MI, USA

<sup>2</sup>Department of Vascular Surgery, University Medical Center Utrecht, the Netherlands

<sup>3</sup>Policlinico San Donato IRCCS, Thoracic Aortic Research Center, San Donato Milanese, Italy

<sup>4</sup>Department of Biomedical Engineering, University of Michigan, Ann Arbor, MI, USA

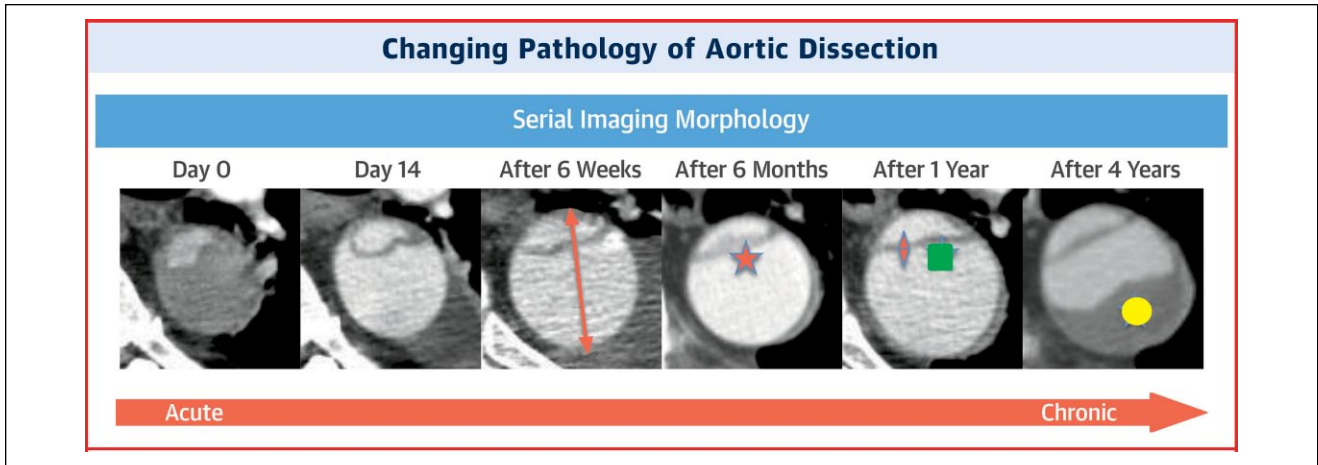
<sup>5</sup>Department of Biomedical Sciences for Health, University of Milan, Italy

Invited commentaries published in the *Journal of Endovascular Therapy* reflect the opinions of the author(s) and do not necessarily represent the views of the *Journal*, the INTERNATIONAL SOCIETY OF ENDOVASCULAR SPECIALISTS, or SAGE Publications Inc.

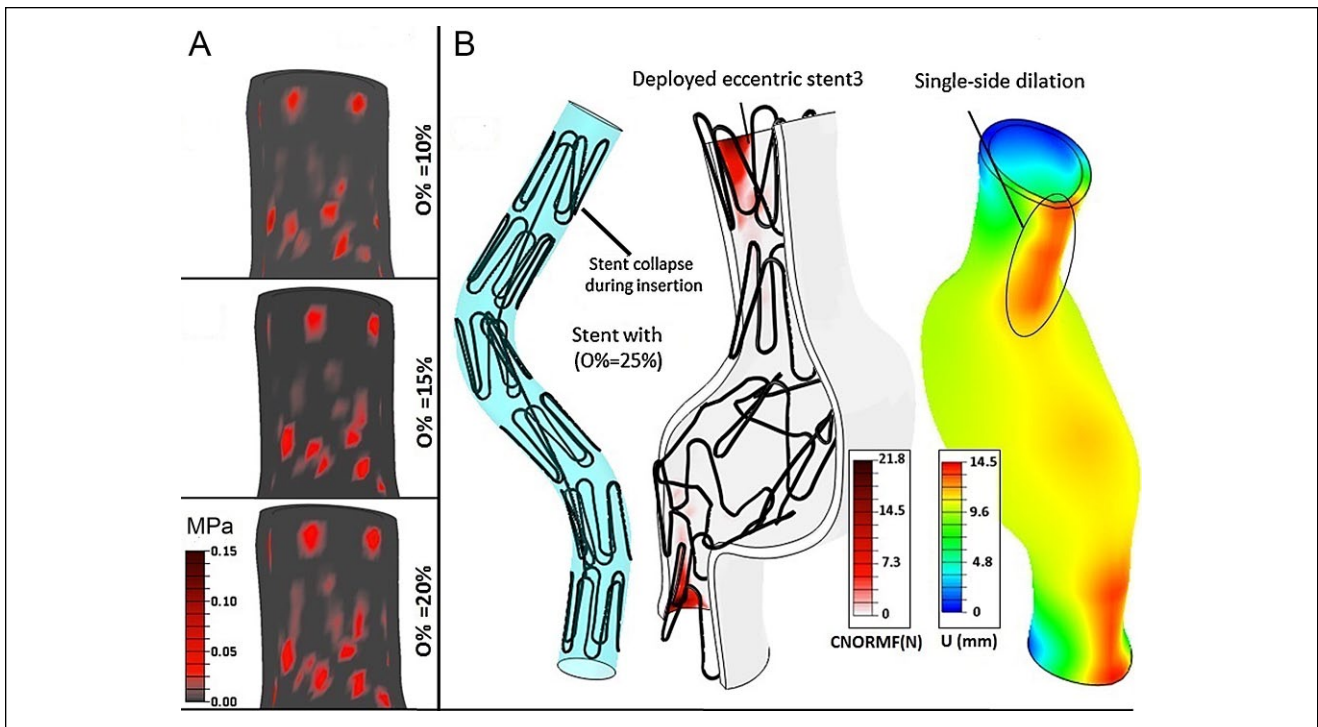
## Corresponding Author:

Theodorus van Bakel, Department of Surgery, University of Michigan, 2101 Taubman Center, 1500 East Medical Center Drive, Ann Arbor, MI 48109 USA.

Email: [vanbakel@med.umich.edu](mailto:vanbakel@med.umich.edu)



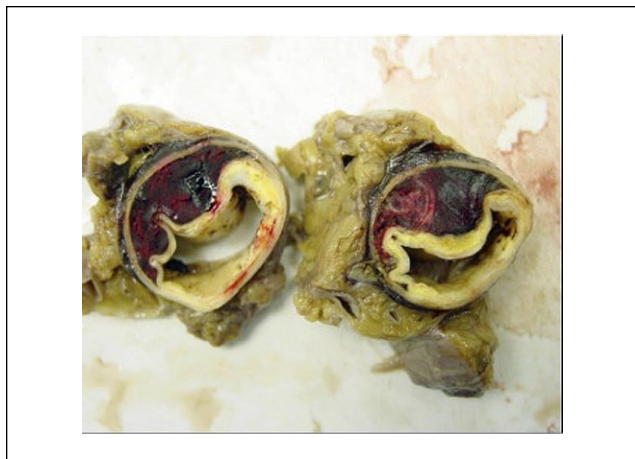**Figure 1.** Changing morphology over time of an individual patient’s type B dissection captured by good quality computed tomography images at the same aortic level. Please note the (1) marked early increase in aortic diameter (orange arrow); (2) intimal thickening over time (orange star); (3) decreased flap motion over time (orange diamond); (4) flap straightening over time (green square); and (5) increased false lumen thrombosis over time (yellow circle). Reprinted with permission from Peterss et al.<sup>4</sup>



**Figure 2.** (A) Contact stresses in the proximal landing zone for different percentages of oversizing (O%). (B) Excessive oversizing (O%=25%) with stent-graft collapse and increased dilatation (U) in the landing zones. Reprinted with permission from Altnji et al.<sup>9</sup>

healthy aortic wall for secure fixation.<sup>9,12</sup> Oversizing of the stent-graft diameter aids fixation in the landing zones, yet excessive oversizing (>20%) needs to be avoided as this is known to induce disadvantageous stress distributions (Figure 2)<sup>9</sup> and is associated with SINE.<sup>13</sup> When planning for TEVAR, stent-graft diameter is often selected based on

the total aortic diameter (true lumen + false lumen). This approach is correct if the true lumen opens completely after stent-graft deployment. In the chronic phase, however, the thick intimal flap and false lumen thrombosis (Figure 3) can restrict expansion of the true lumen. The radial force that resides in the partially unfolded stent-graft increases the



**Figure 3.** Thickened dissection flap with false lumen thrombosis in a patient with a chronic type B dissection. Reprinted with permission from Kasirajan et al.<sup>7</sup>

risk of SINE. Therefore, it is suggested to avoid significant oversizing when planning TEVAR for chronic TBAD.<sup>1,7-9</sup>

Preferably, all patients who will develop postdissection aneurysmal dilatation should be treated in the acute phase. However, it would be harmful to subject patients who may never develop aneurysmal dilatation to the risks of TEVAR-related complications such as retrograde dissection, stroke, and spinal cord ischemia. The challenge therefore remains selecting those patients who will develop aneurysmal dilatation from those who will not. At this point, no guidelines are available to aid early patient selection. Future research may fill this void, using 4-dimensional flow magnetic resonance imaging and patient-specific computational modeling to identify hemodynamic characteristics that can predict the risk of aneurysmal dilatation following uncomplicated TBAD.

### Declaration of Conflicting Interests

The author(s) declared no potential conflicts of interest with respect to the research, authorship, and/or publication of this article.

### References

1. Erbel R, Aboyans V, Boileau C, et al. 2014 ESC guidelines on the diagnosis and treatment of aortic diseases: Document covering acute and chronic aortic diseases of the thoracic and abdominal aorta of the adult. The Task Force for the Diagnosis

and Treatment of Aortic Diseases of the European Society of Cardiology (ESC). *Eur Heart J*. 2014;35:2873–2926.

2. Fattori R, Montgomery D, Lovato L, et al. Survival after endovascular therapy in patients with type B aortic dissection: a report from the International Registry of Acute Aortic Dissection (IRAD). *JACC Cardiovasc Interv*. 2013;6:876–882.
3. Menichini C, Pirola S, Guo B, et al. High wall stress may predict the formation of stent-graft-induced new entries after thoracic endovascular aortic repair. *J Endovasc Ther*. 2018;25:571–577.
4. Peterss S, Mansour AM, Ross JA, et al. Changing pathology of the thoracic aorta from acute to chronic dissection: literature review and insights. *J Am Coll Cardiol*. 2016;68:1054–1065.
5. Brunkwall J, Kasprzak P, Verhoeven E, et al. Endovascular repair of acute uncomplicated aortic type B dissection promotes aortic remodelling: 1 year results of the ADSORB trial. *Eur J Vasc Endovasc Surg*. 2014;48:285–291.
6. Qin YL, Wang F, Li TX, et al. Endovascular repair compared with medical management of patients with uncomplicated type B acute aortic dissection. *J Am Coll Cardiol*. 2016;67:2835–2842.
7. Kasirajan K, Milner R, Chaikof EL, et al. Late complications of thoracic endografts. *J Vasc Surg*. 2006;43(suppl A):94A–99A.
8. Rohlfs F, Tsilimparis N, Diener H, et al. Chronic type B aortic dissection: indications and strategies for treatment. *J Cardiovasc Surg (Torino)*. 2015;56:231–238.
9. Altnji HE, Bou-Said B, Walter-Le Berre H. Morphological and stent design risk factors to prevent migration phenomena for a thoracic aneurysm: a numerical analysis. *Med Eng Phys*. 2015;37:23–33.
10. Figueroa CA, Taylor CA, Chiou AJ, et al. Magnitude and direction of pulsatile displacement forces acting on thoracic aortic endografts. *J Endovasc Ther*. 2009;16:350–358.
11. Marrocco-Trischitta MM, van Bakel TM, Romarowski RM, et al. The Modified Arch Landing Areas Nomenclature (MALAN) improves prediction of stent graft displacement forces: proof of concept by computational fluid dynamics modelling. *Eur J Vasc Endovasc Surg*. 2018;55:584–592.
12. Marrocco-Trischitta MM, de Beaufort HW, Secchi F, et al. A geometric reappraisal of proximal landing zones for thoracic endovascular aortic repair according to aortic arch types. *J Vasc Surg*. 2017;65:1584–1590.
13. Nauta FJ, Conti M, Kamman AV, et al. Biomechanical changes after thoracic endovascular aortic repair in type B dissection: a systematic review. *J Endovasc Ther*. 2015;22:918–933.